

## HISTOPATHOLOGICAL CHANGES INDUCED BY CESTODE PARASITE IN FRESH WATER MURREL

Laxma Reddy B<sup>1\*</sup> and Benarjee G<sup>2</sup>

<sup>1,2</sup>Fisheries Research Lab, Department of Zoology, Kakatiya University, Warangal-506 009.  
Andhra Pradesh, India.

E-mail: drblaxmareddy@yahoo.co.in

### ABSTRACT

*Lytocestus indicus* is found infected to the stomach of fresh water murrel, *Channa punctatus*. This parasite brought about severe histopathological changes in the infected murrel. Histopathological changes include damage of villi, inflammation, fibrosis associated with hyperplasia and metaplasia, epithelial necrosis, vacuolation of submucous cells and dilation of blood vessels. The present paper deals with the histopathological changes in the stomach of fresh water murrel, *Channa punctatus*.

**Key words:** *Channa punctatus*, *Lytocestus indicus*, Histopathology..

### INTRODUCTION

Helminths infect almost all the regions of the alimentary tract of fish. Any damage to the alimentary canal will alter the physiological activities of fish. For cestode parasites the most favourable and selected site is the alimentary canal, and the reason is to meet their primary need of food from the host. Cestodes have also been found to infect many fish and cause pathological effects on the host. In some cases the parasites have caused severe changes in the host. Others who have reported on the cestode infection in fishes are Ahmed and Muhammad, 1979; Satpute and Agarwal, (1974a and 1974 b); Pronina and Pronin, (1982); Chakravarthy and Tandon, 1984; Chakravarthy and Veena, 1989; Chubb, 1982; Hasnain, 1992. It is observed that the cestodes cause histopathological changes in fresh water fishes (Bose and Sinha, 1983; Hayunga, 1977 & 1979; Lyngdoh, 1995; Lyngdoh and Tandon, 1996; Mackiewicz et al., 1972; Ramadevi, 1973; Bunoti, 1980; Zaman and Leong Takseng, 1988). Therefore, an attempt has been made to assess the histopathological

changes induced by the parasite, *Lytocestus indicus* in the stomach of *Channa punctatus*.

### MATERIALS AND METHODS

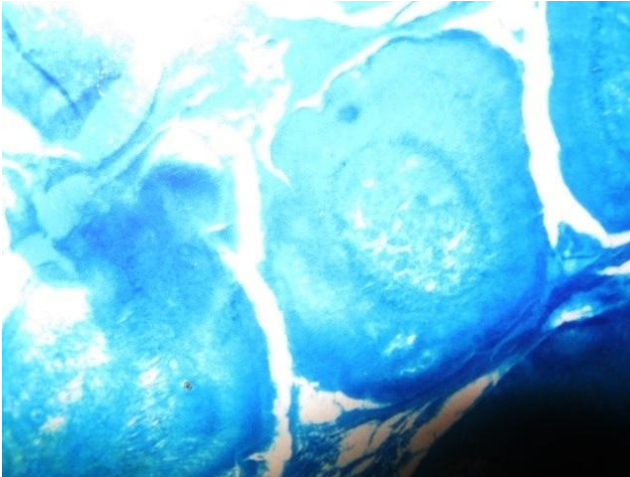
Pieces of the infected and uninfected stomach of fresh water murrel, *C. punctatus* and were fixed in Bouin's, Susa, Carnoy and Zenker's fluid for the histopathological and histochemical studies (Pearse, 1968 and Bancroft, 1975). They were dehydrated by graded alcohol, cleared and embedded in paraffin wax. A battery of histochemical tests were applied on the microtome cut sections of stomach gives exact localization of the parasite, the damage caused at a particular site of the tissue and the change in the chemical nature of the tissue of the organ affected.

### RESULTS AND DISCUSSION

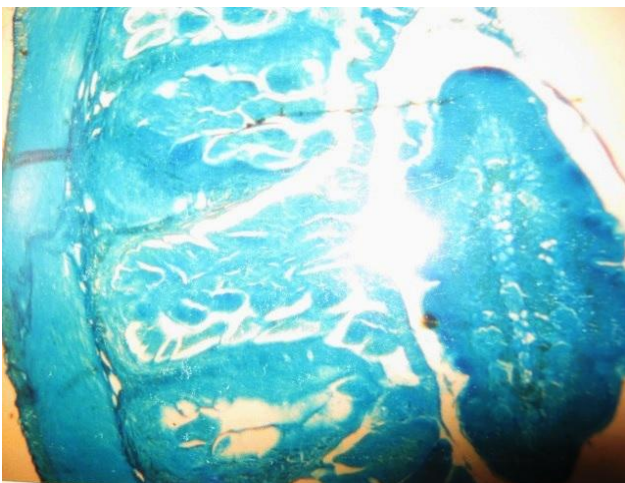
After cestode parasite infection there is a drastic alteration which leads to the destruction of the internal anatomy, resulting in the total change of its appearance. Infected fish includes shortening

of villi, thickening of the muscle layer, destruction of the villi, hold fast penetration of the mucosa and the damage of both the mucous and submucous membranes.

**Figure-1. T.S of infected stomach shows vacuolation**



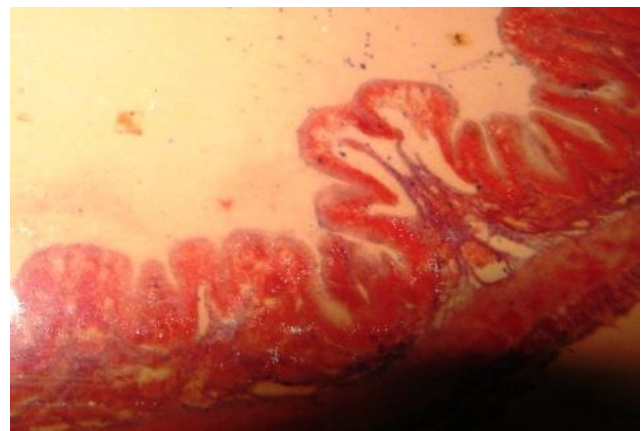
**Figure-2. T.S of infected stomach with parasite**



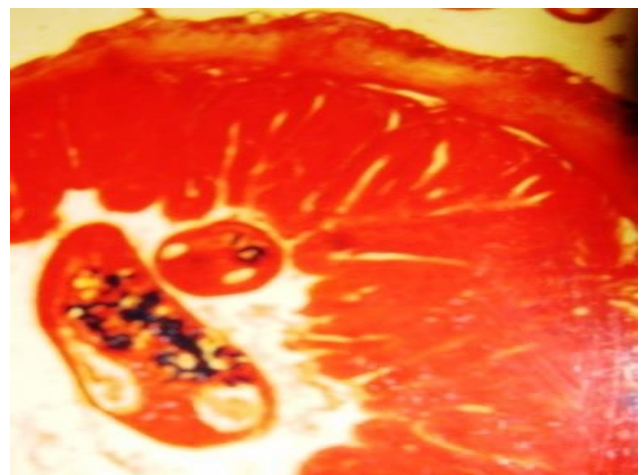
The infestation of helminth parasites to the fish brings vital changes in the host body. These changes not only reflect on the physiological status of the organism but many important physiological functions are interrupted. The energy yielding process of the body is generally effected thus the physicochemical constituents of various regions of the host effected. The infection may bring oral physiological changes in the host but infection to the stomach interferes with the process of digestion of the food and

maldigestion may cause various metabolic disorders. The stomach is completely washed off. It resulted into a major disruption of the structural organization of the stomach. Flattening of the surface epithelium, complete damage of lamina propria and oedema of submucous membrane was noticed. The muscular layer in the columnar cells present in it is completely degenerated necrosis and the raising of secondary folds of the muscularis layer is also evidenced.

**Figure-3. T.S of infected stomach shows shortening of villi**



**Figure-4. T.S of infected intestine showing parasite**

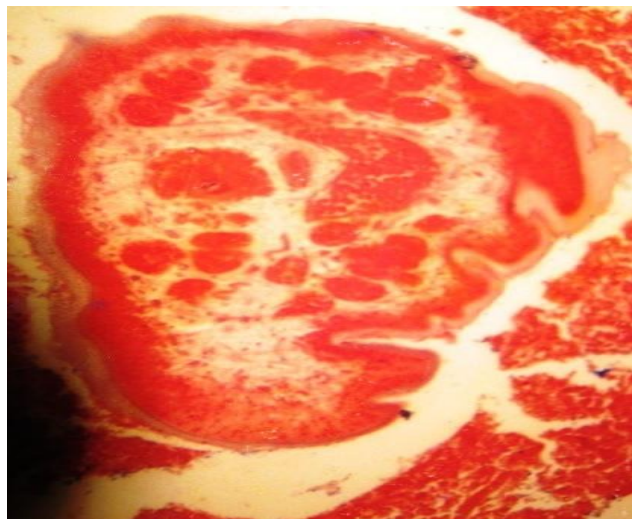


The pathological lesion, the presence of cysts in different region of the stomach results in the damage of tissue of the stomach due to parasitic infection was clearly evidenced in the present study. The blood vessels have undergone marked

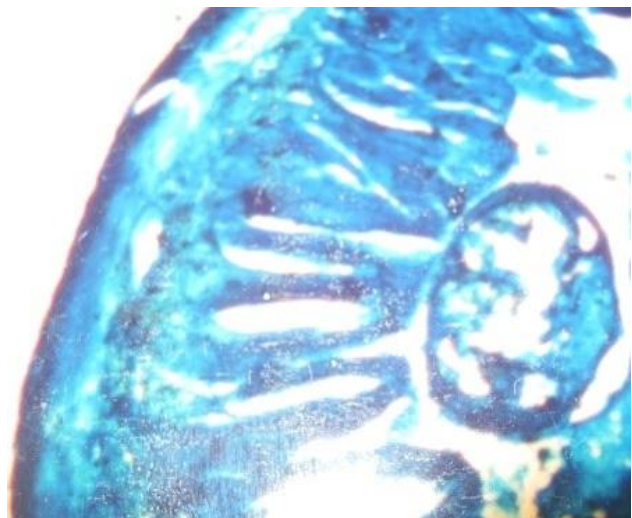


dilation and the submucosa slugging into the mucous layer.

**Figure-5. T.S of infected stomach with enlarge parasite**



**Figure-6. T.S of infected stomach showing the attachment of parasite**



In the present study it is observed that the stomach highly effected due to helminth infestation which was evidenced by total eruption of villi from the mucous membrane which resulted to a major disruption of the structural organization of the organ which might have profound influence on the nutrition and digestion process of the fish. Satpute and Agarwal (1974) have observed similar type of histopathological changes in the duodenum of *Clarias batrachus* due to the infection of a

parasite *Djombangia indica*, in which the parasite effects were prominently noticed in the histology of the duodenum of infected fish and it was observed that the muscularis layer became thick and the villi have become shorter. The enormous thickening of muscle layer of the digestive tract must effect the peristalsis and also the general metabolism and consequently the fish became sluggish and moribund. Satpute and Agarwal (1974) observed histopathological changes in the stomach of *Clarias batrachus* infected with *Lytocestus indicus* Kanth and Srivastava (1984) observed same kind of histopathological changes in the intestine of *Heteropneustes fossilis* infected with monozoic caryophyllid tape worm, *Lytocestoides fossilis*. Rees (1967) observed inflammation fibrosis associated with hyperplasia and metaplasia in a cestode infection. Sircar and Sinha (1980) observed degenerative changes include hypertrophy and hyperplasia of the intestinal villi Ahmad and Muhammad (1979) observed shallow ulcers in host fish due to *Lytocestus indicus*. Similar observations were made by Kanth and Srivastava (1984), Sircar and Sinha (1980), Ahmad and Muhammad (1979), Rees (1967), Stirewatt (1963) and the damage of the host tissues may be due to secretion of lytic enzymes and penetrative damage caused by the parasite when it establishing its position in the host.

The present findings further agrees with the view of Laxma Reddy and Benarjee (2007): Laxma Reddy et al. (2006); Benarjee and Laxma Reddy (2006), Laxma Reddy and Benarjee (2008, 2011 & 2013). These histopathological changes within the host's tissue, stomach show a definite habitat preference.

## CONCLUSION

There is a necessary to study the pathological effects in the naturally occurring fish. Effective formulated drugs have been used to expel the parasites from the body without causing any damage to the host itself. Drugs control the helminth infections which are not only of medical importance but also of economic, in

order to increase the health standard and biological productivity.

### ACKNOWLEDGEMENTS

The authors are thankful to the Head, Department of Zoology, Kakatiya University for providing the facilities.

### REFERENCES

1. **Ahmad, A.T. and Muhammad's. 1979.** Fish pathol.,1-14.
2. **Bancroft. J.D. 1975.** Histochemical techniques Butterworths, London and Boston.
3. **Benarjee. G. and Laxma Reddy. B. 2006.** Histopathological & Histophysiological changes in the duodenum due to infestation with *Djombangia indica*. *J. of Curr. Sci.*9(2):647-654.
4. **Bose, K.C. and Sinha, A.K. 1983.** Histopathology of *Clarias* attributable to the intestinal cestode *Lytocestus indicus*. *Proc. Natl. Acad. Sci. India. Sec.B. Biol. Sci.* 53:226-230.
5. **Bunoti, W.M.A.N. 1980.** The prevalence and pathology of the cestode *Polyonchobothrium clarius* (Woodland-1925) in the teleost *Clarias mossambicus* (peters) *J. Fish. Dis.*39(3):223-230.
6. **Chakravarthy, R and Veena. 1989.** Caryophylliasis in the cat fish, *Clarias batrachus* L. some histopathological observations. *Proc. Indian Acad. Sci. Anima Sci.* 98:127-132.
7. **Chakravarthy. R. and Tandon, V. 1989.** Histochemical studies on *Lytocestus indicus* and *Djombangia penetrans*, Caryophyllidean cestode parasites *Clarias batrachus* (L). *Helminthologia* (British). 26:259-274.
8. **Dap, R.A., (2009).** Histopathology of the cestode parasites, *Gensus Cotugia* (Diamare, 1893) from *Galus domesticus*..U.P. *J. Zoo.* 29(3):423-426.
9. **Chubb, J.C. 1982.** Seasonal occurrence of helminthes in fresh water fishes. Part.IV. Adult Cestoda, Nematoda and Acanthocephala. *Advances in Parasitol.* 20;1-292.
10. **Hasnain, M., 1992.** New cestoda *Senga chauhani* sp.nov. from a fish host *Channa puctatus* from Jamshedpur. *Indian J. Helminthol.* 44(2):121-127.
11. **Hayunga, E.G. 1977.** Scolices of three caryophyllied tape worm relationship of pathology and site of secretion in host intestine. *Diss, Abs. Int.*pp.38-39.
12. **Hayunga, E.G. 1979.** Observations on the intestinal pathology caused by 3 caryophyllaeid tape worms of the White sucker *Catostomus commersoni* Lacepede. *J. Fish. Dis.*2:239-248.
13. **Kanth L.K and Srivastava L.P. 1984.** Host-parasite relations in monozoic tape worm, *Lyto-cestoides fossilis* infection of fresh water fish, *Heteropneustes fossilis* (Bloch). *Currrent science.* 53: 11-22.
14. **Lyngdoh R.D. 1995.** Some caryophyllidean cestodes. parasitizing edible cat fishes a morphological, histocytological and histochemical approach to the host parasite relationship. North Eastern Hill Uni,Shillang.
15. **Lyngdoh, R.D. & Tandon,V. 1996.** Surface topographical and ultrastructural studies on caryophyllaedian cestode, *Lytocestus indicus* (Lytocestidae) *J. Parasitol. App. Animal Biol.* 5;67-74.
16. **Laxma Reddy B and Benarjee. G. 2007.** Histopathological changes in the stomach of *Clarias batrachus* due to *Lytocestus indicus*. *J. Agric. Biol. Res.*23(1):251-257.
17. **Laxma Rddy, B, Benarjee, G. and Rajender, J.2006.** Biosttistical indices on the occurrence of cestode parasite, *Lytocestus indicus* infection in the fresh water cat fish, *Clarias batrachus* at the warangal region of Andhra Pradesh. *J. Natcon.* 18(2)343-348.
18. **Laxma Reddy B and Benarjee G. 2013.** Intestinal histopathology of trematode infected fish, *channa striatus*. *Biolife* 1(1), 29-31.
19. **Laxma Reddy B and Benarjee G. 2008.** population dynamics of cestode parasite found in fresh water fish. *Channa punctatus*. *J. Ecobiol.* 22(4):349-355.
20. **Laxma Reddy B and Benarjee G. 2011.** The population dynamics of Endohelminths

- of fresh water fishes at Warangal, Andhra Pradesh. *J. Natcon* 23(1):141-144.
21. **Mackiewicz, J.S., Cosgroove, G.E. and Gude, W.D. 1972.** Relationship of pathology of Scolex morphology among caryophyllaeid cestode. *Z. Parasitenkd.* 39:233-246.
  22. **Pearse, A.G.E. 1968.** Histochemistry. Theoretical and applied 2<sup>nd</sup> Edition, Little Brown and Company., Boston, MSS.
  23. **Pronina, S.V. and Pronin, N.M. 1982.** Structure of the digestive tract of healthy pike *Esox lucius* (Esoxidae) and of those fishes infected with the cestode, *Trisaenophorus* (Pseudo R phyllidea, Triaeonophoridae) *VOPR IKHTIOL.*,22(4): 641-648.
  24. **Ramadevi, P. 1973.** *Lytocestus longocollis* sp. Nov. (Cestoidea: Caryophyllidea) from the catfish *Clarias batrachus* (L) *Indian. J. Helminthol.*,47(4) :415-420.
  25. **Rees, G. 1967.** *Helminthos Abstr*, 36,1.
  26. **Sircar, M and Sinha, D.P., 1980.** *Indian J. Animal. Res.*,14 ;53.
  27. **Stirewatt, M.A. 1963.** Chemical biology of secretions of larval helminthes. *Ann. NY Acad. Sci.*,113;36-53..
  28. **Satpute L.R. and Agarwal S.M. 1974 a.** Seasonal infection of *Clarias batrachus* (L) by *Lytocestus indicus* Moghe, 1931 and parasitic effects on its hematology and histopathology. *Ind. J. Exp. Biol.* 12:584-586.
  29. **Satpute, L.R and Agarwal, S.M. 1974 b.** Diverticulosis of the fish duodenum infected with cestodes. *Ind. J. Exp. Biol.* 12; 584-586.
  30. **Zaman, Z. and Seng, L.T. 1990.** Distribution patterns of a caryophyllaeid cestode in the gut of fish of the *Clarias* genus from Pendang, Malaysia. *Dhaka Uni. Stud. Part.E. Biol.Sci.*,5(2):115-122.

DOI:<https://dx.doi.org/10.5281/zenodo.7197530>

Received: 14 January 2014;

Accepted: 28 February 2014;

Available online : 9 March 2014