

First report of three species of *Argulus* (Crustacea: Branchiura) infesting on red-can Oranda gold fish (*Carassius auratus auratus*) in India

Mandira Saha¹ and P.K.Bandyopadhyay^{2*}

^{1,2} Parasitology Laboratory, Department of Zoology, University of Kalyani, Kalyani 741235, West Bengal, India

*Email: prabir0432@hotmail.com

ABSTRACT

Ornamental fishes are considered as one of the most important means of home entertainment, because of its diversity and beauty of picturesque colors. This research work has been conducted to show that the ornamental fish mainly Red Can Oranda Gold fish (*Carassius auratus auratus*) are mainly affected with parasites like *Argulus* sp. and also reveal the prevalent and unforeseen parasitic infection in commercially available ornamental fishes which may credit to their marketable value. During the period of March 2014 to April 2015, around 30 numbers of fish farms of West Bengal have been surveyed and three species of *Argulus* namely, *A. coregoni*, *A. japonicas*, and *A. foliaceus* have been isolated and identified from the skin or gill of the fresh water fish species. Clinical signs in infected fish include scratching on aquariumwalls, erratic swimming, and poor growth. It causes pathological changes due to direct tissue damage and secondary infections. In the present study, it has been noticed that crustacean parasites were prevalent during pre-monsoon season but their intensity was very less during the other season of the year. This is the first report of infection with three species of *Argulus* of Red Can Oranda Gold fish (*Carassius auratus auratus*) in India.

Key words : Red Can Oranda Gold fish, *Argulus foliaceus*, *Argulus japonicas*, *Argulus coregoni*, First reporting, Prevalence, India

INTRODUCTION

Ornamental fishes are considered as one of the most important means of home entertainment, because of its diversity and beauty of picturesque colours. Also, ornamental fishes are used for commercial purposes as a new industry all over the world. Argulosis is the most common crustacean diseases affecting ornamental fishes (Eissa 2002; Eissa *et al.* 2002a; Eissa and Mohamed 2004 and Al-Dulaimi 2010), the disease may cause significant

morbidity and mortality in cultured fish populations especially in heavy infestation (Mousavi *et al.* 2011; Sharma *et al.* 2012).

The genus *Argulus* (Crustacea: Branchiura), or fish louse, are common parasites of freshwater fish (Bauer 1991; Yildiz and Kumantas; 2002). According to Eissa (2002) and Eissa and Mohamed (2004), *Argulus* contributes most common disease Argulosis (a crustacean diseases) affecting ornamental fishes which is specifically common in goldfish and Koi (Noga 2010). The most common members of the Branchiura belong to the genus *Argulus*, so called fish lice. Many of the species are parasitic on marine fishes, and about 15 species are found to be infected the freshwater fishes (Bauer *et al.* 1991 and Bykhovskaya-Pavlovskaya 1964). The parasites may be seen with naked eye since these parasites are 5- 10 mm in size and consist of a head, thorax, and abdomen. The head is covered by a flattened horseshoe-shaped carapace, maxillipeds, per oral sting, and basal glands. The thorax has four segments, each bearing a pair of swimming legs. The abdomen is a simple bilobed segment. When

How to cite this article:

Mandira Saha and P.K.Bandyopadhyay (2015). First report of three species of *Argulus* (Crustacea: Branchiura) infesting on red-can Oranda gold fish (*Carassius auratus auratus*) in India. *Biolife*, 3(4), pp 813-819.

seen from the dorsal side, two prominent movable compound eyes are visible in the head region (Bykhovskaya-Pavlovskaya 1964; Soulsby 1982). In its life cycle, mature females leave the host and lay several hundred eggs on vegetation and various objects in the water (Yıldız 2002). Eggs are ovoid in shape and are covered by a gelatinous capsule. Depending on the temperature, 40-100 days are required for completion of the life cycle (Yıldız 2002). Adults may live free from the host for up to 15 days. Parasites insert a sting located pre-orally to inject digestive enzymes into the body (Bauer 1991). They then suck out the liquefied body fluids using their proboscis-like mouth. Feeding can take place on the skin or in the gills of the fish causing intense irritation and tissue damage (Bauer 1991; Richards 1977). Localized inflammation is often seen at the site. Opportunistic bacteria such as *Aeromonas* or *Pseudomonas* can sometimes infect these damaged areas leading to skin ulceration (Abele 1982; Burgu, 1988). In addition to physical damage, affected fish are subject to severe stress, which often leads to secondary parasitic infestations with a white spot and *Costiasp.* (Bauer 1991). *Argulus* sp. is found nearly worldwide with about 150 species known at present. Three species documented in Europe are *Argulus foliaceus*, *Argulus japonicas* and *Argulus coregoni*. *Argulus foliaceus* also occurs on brown trout, as well as perch, trench, carp, pike and bream. Besides the damage and stress caused by *Argulus* itself, one of the main worries for fish producers is the associated secondary infestation that can result from infestations with parasite. Several studies have examined on the role of parasites as vectors for other diseases such as Aeromoniasis or Pseudomoniasis (Bauer 1991; Richards 1977).

The aim of this study is to report for the first time of three species of *Argulus* causing harm to Red can Oranda goldfish in India followed by the prevalence of this *Argulus*.sp.

MATERIALS AND METHODS

Sampling:

During the period of March 2014--April 2015, around thirty fish farms belonging to five districts (Nadia, Hooghly, Howrah ,North 24-pargana and South 24-pargana) have been surveyed and fish specimens were collected and brought alive to the Laboratory and kept in the small water bodies (vats) in the vicinity of the University.

Parasitological examination:

Total number of 730 fishes was observed for detection of ectoparasitic infection. Parasitological examination was carried out for the detection and identification of the external parasites on the skin, gills and the accessory respiratory organs of the samples.

Clinical examination:

Clinical examination of fish species, *C. auratus auratus* was adopted using the methods as described by Lucky, 1977 for the determination of any lesions or abnormalities on the external body surface.

Isolation of pathogens:

The external body surface and gills of fish species, *C. auratus auratus* were carefully examined macroscopically. The detected parasites, which could be easily seen with naked eyes were collected by using fine brush, washed for several times in warm saline solution and left in refrigerator at 4°C for complete relaxation (Eissa, 2002). The collected crustaceans were counted, fixed in 70% ethanol, preserved in alcohol glycerol (4:1) for permanent mounts, cleaned and mounted according to the methods described by Lucky (1977).

Identification of infesting species:

Identification and morphometric characteristics were conducted according particularly to Bykhovskaya-Pavlovskaya et al (1962) and Rushton-Mellor (1994). Then the microscopical photos were snapped by Olympus CX 41(10X magnification) model.

Statistical analysis:

Prevalence, mean intensity and abundance concepts as suggested by Margolis et al. (1982) were used in the present study.

$$\text{Prevalence (\%)} = \frac{\text{No. of Infected fish} \times 100}{\text{Total number of fish examined}}$$

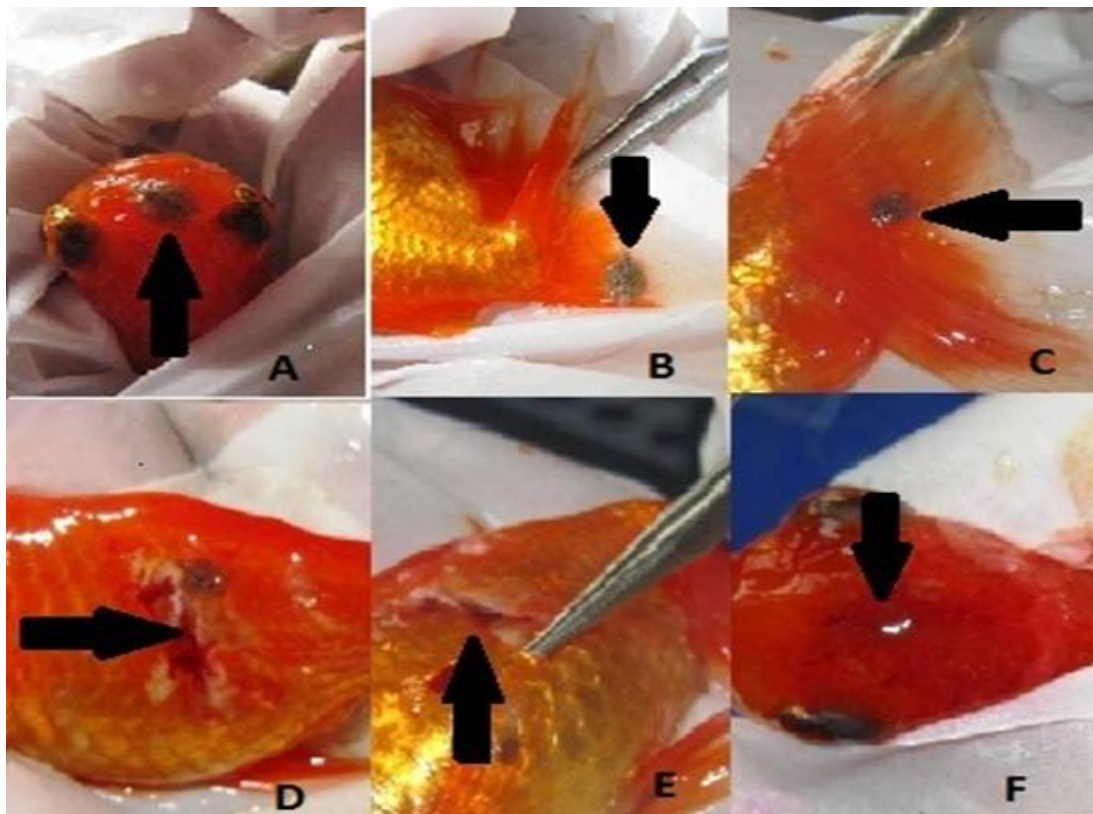
$$\text{Mean Intensity (Unit)} = \frac{\text{No. of collected parasite / (s)}}{\text{No. of infected fish}}$$

$$\text{Abundance (Unit)} = \frac{\text{Number of parasites / (s)}}{\text{Number of fish examined}}$$

RESULTS

During the survey work, total of 730 specimens of the fish have been collected, out of which 450 fishes were found to be infected with crustacean parasites. The infected fishes were identified by their irritating and sluggish movement. Heavily infected fishes were showed reddish appearance throughout their whole body specially fins and head portion (Fig.1A-F).The clinical symptoms of naturally infected fish with argulosis were revealed the presence of abnormal swimming ,erratic movements, rubbing themselves against the wall of the tank, frayed fins and off food.

Figure-1.(A,B,C) Photograph showing *Argulus* sp. on the tail, fin and head of goldfish and (D,E) showing loosening of scales, hemorrhagic spot and excessive mucous on the lateral side F Showing ulcerations, hemorrhagic areas with excess of mucous at the head region on the external body surface.



Development of inflammatory lesions at the site of parasitic existence, characterized by huge secretion of mucous and haemorrhages causing lesion of the injured areas were observed on the skin and fin (Fig.1.D,E,F).

However, some infested fishes showed nervous manifestation with easily detached scales and abraded areas (Fig.1.D,E).

In this study, three species of *Argulus* namely, *A. coregoni*, (Fig: 2(A-D) and Fig. 3-A), *A. japonicas*(Fig: 2(E,F) and Fig. 3-B) and *A. foliaceus* (Fig: 2(G-J) and Fig. 3-C) have been identified and differentiation of these three species have also been made, which are as follows.

➤ ***Argulus coregoni*: (Fig: 2(A-D) and Fig. 3-A)**

A. coregoni has acuminate abdomen lobes and 12 mm body length, Posterior lobes of carapace are not extend beyond the beginning of the abdomen and posterior incisures of abdomen reach beyond middle of the body

➤ ***Argulus japonicas*: (Fig: 2(E,F) and Fig. 3-B)**

A.japonicas 4-8 mm in length and posterior lobes of cephalothoracic carapace extended beyond the beginning of abdomen, Round lobes (though more pointed than *A. foliaceus*) and covered marginally with small spines and Posterior incisures of abdomen reach middle of the body.

➤ ***Argulus foliaceus*: (Fig: 2(G-J) and Fig. 3-C)**

In case of *A. foliaceus* the length of the parasites is 6-7 mm in length and has rounded lobes of abdomen which covered marginally with small spines, the posterior emargination not reaching the mid-line and posterior lobes cephalothoracic carapace not extended beyond the beginning of abdomen. The morphometric comparison has been done using morphological keys mention in (Table 1).

Crustacean parasites were prevalent during Pre-monsoon season but their intensity was very less

Table.1: Differences among *Argulus* species considered in this study.

Species	Length of body (mm)	Posterior lobes of carapace	Abdomen	Posterior incisures of abdomen
<i>A. foliaceus</i>	6-7	Not extend beyond beginning of the abdomen	Round lobes is covered marginally with small spines	Not reach middle
<i>A. japonicus</i>	4-8	Extend beyond level of the middle of abdomen and carapace covers forth leg	Round lobes (though more pointed than <i>A. foliaceus</i>)and covered marginally with small spines	Reach middle
<i>A. coregoni</i>	12	Not extend beyond beginning of abdomen	Acuminate lobes without any small spines	Reach beyond middle

Figure-2. (A,B) Photograph showing Dorsal and Ventral view of male *Argulus coregoni* , (C,D) showing Dorsal and Ventral view of female *Argulus coregoni* , (E) showing dorsal view of male *Argulus japonicus* and (F) showing dorsal view of female *Argulus japonicus*(G,I) Photograph showing dorso-anterior and posterior view of *Argulus foliaceus* and (H,J) showing ventro-anterior and posterior view of *Argulus foliaceus*.

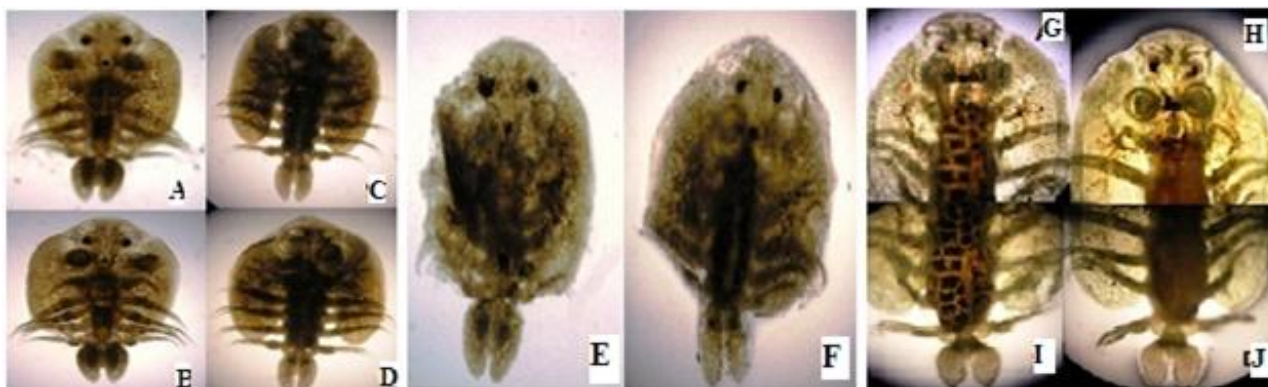


Figure-3.(A) Showing the schematic diagram of *Argulus coregoni*, (B) *Argulus japonicus* and (C) *Argulus foliaceus*. Scale Bar–5 µm.

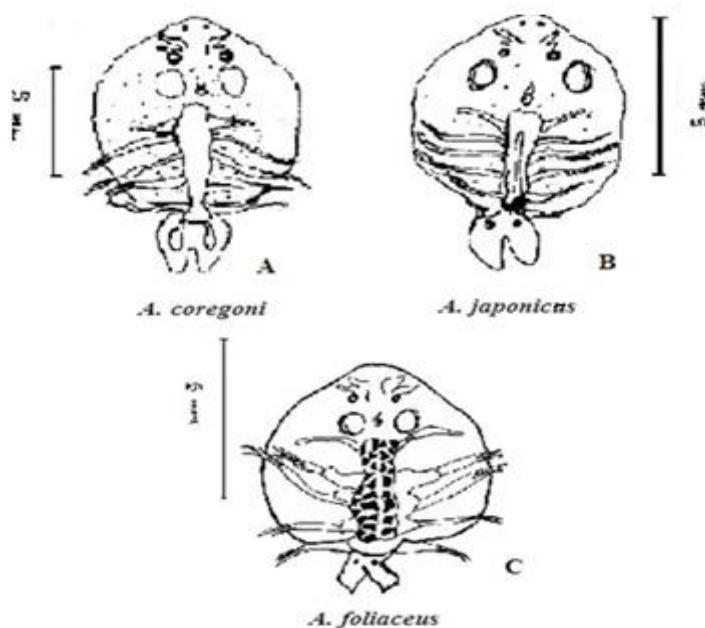
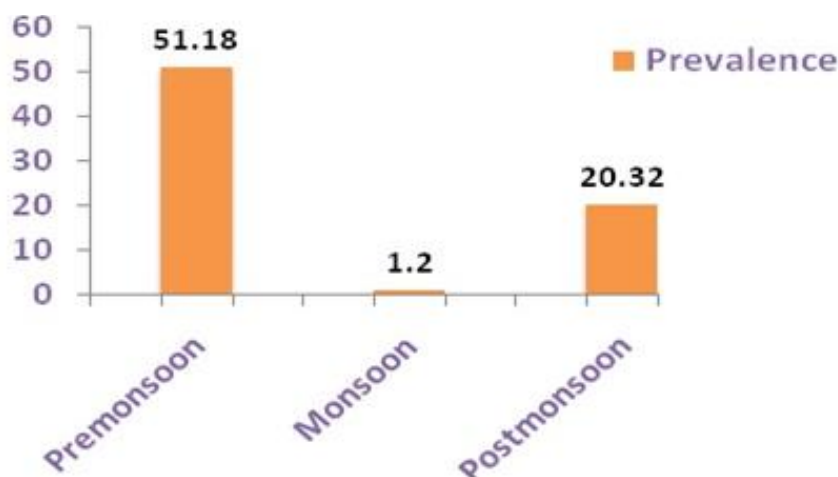


Figure-4. Graphical representation of Season wise prevalence of *Argulus* sp. in Red Can Oranda Gold fish.**Table-2.** Season wise prevalence, mean intensity and abundance of *Argulus* sp. in Red Can Oranda Gold fish

Season	No. of Fish Examined	No. of fish infected	No. of collected parasites	Prevalence	Mean Intensity	Abundance
Pre-Monsoon	170	87	602	51.18	6.92	3.54
Monsoon	250	3	4	1.20	1.33	0.02
Post-Monsoon	310	63	192	20.32	3.05	0.62

during the other season of the year. Seasonal fluctuation of this crustacean parasites in the fish has been mentioned in (Fig: 4). The prevalence and mean-intensity (Table.2) was more in Pre-monsoon and that too followed by Post-monsoon and Monsoon and in succession (Table.2). The Abundance (unit wise) differed season to season and there was a drastic fluctuation has been occurred. It was recorded more in Pre-monsoon season and least in Monsoon (Table.2).

DISCUSSION

Argulus sp. have been reported from different fish species worldwide (Buchmann and Bresciani 1997; Molnar et al. 1998; Geldiay 1974; Sariyyupoglu 1991; Noga 2010; Notash 2013; Toksen 2006; Yildiz and Kumantas 2002; Ekingen 1976; Burgu et al. 1988; Adnan 2014; Abd el-mohsen 2013). In Iran, *Argulus* spp. were reported from different hosts between 1984 and 2012 (Peygan 1999; Azadikhah et al 2009; Behrouzfar et al 2009; Jaameei et al 2009; Mehdizadeh 2009; Mokhayer 2006; Mokhayer and Ebrahimzadeh Mousavi 2009; Mosafer et al 2009; Noaman et al 2010; Ebrahimzadeh Mousavi 2011; Shahab Notash 2012). In India Chanda et al. et al., 2011 and Kaur et al., 2014 reported *Argulus* sp. from Gold fish and Koi fish respectively but reporting of three species namely, *Argulus coregoni* (Thorell, 1864), *Argulus japonicas* (Thiele, 1900), and *Argulus foliaceus*

(Linnaeus, 1758) are first time in Red Can Oranda Gold Fish *Carassius auratus auratus* in India.

The morphometric comparison among these three species on the basis of their length, posterior lobes of carapace, abdomen, posterior incisures of abdomen have been made i.e. *A. coregoni* has acuminate abdomen lobes and 12 mm body length, in *A. japonicas* posterior lobes of cephalothoracic carapace extended beyond the beginning of abdomen but *A. foliaceus* has rounded lobes of abdomen, the posterior emargination not reaching the mid-line and posterior lobes cephalothoracic carapace not extended beyond the beginning of abdomen. This findings matches with the findings of Yildiz and Kumantas (2002).

Clinical signs and behaviours observed in infected fish were in accordance with the cases reported by Toksen (2006), Yildiz and Kumantas (2002), Noaman (2010). The present study revealed that the clinical signs of naturally infected fish species with different *Argulus* sp. were erratic movements, abnormal swimming, rubbing themselves against the wall of tank, frayed fins, off food, flashing, scratching, mucus increase and poor growth as well as blood spots in the surface of their body and fins were observed. These signs are occurred due to the attachment and feeding activity of *Argulus* sp. by sucking body fluids of the host with their proboscis like mouth. This result corroborated with the observations of some authors namely, Yildiz and Kumantas (2002), Toksen (2006), Noaman et al. (2010), Elissa (2002), Noga (2010), Adnan

AL-Darwesh (2014), Abd el-mohsen (2013). However, repeating piercing of the skin *Argulus* may inject a toxic enzymes causing irritation, resulting in the development of inflammatory lesions characterized by increase mucous secretion, haemorrhages and necrosis of the injured areas (Toksen 2006; Noaman *et al.* 2010; Noga 2010; Purivirojkul 2012; Sharma *et al.* 2012; Vasilean *et al.* 2012; Myer 2013). However, such secreted toxins by parasite may explain the recorded nervous manifestation in naturally infested fishes in the present study (Vasilean *et al.* 2012).

In the present study seasonal data revealed that the intensity of crustacean parasite *Argulus sp.* infection were high in high temperature and the infection gradually decreased with the fall of temperature during post-monsoon season. These work matches with the observation of Walker (2008). Furthermore, fluctuation of temperature and poor water quality are also responsible for spreading of disease to delicate Oranda gold fish.

CONCLUSION

The study concluded that poor control of importation of fish will cause argulosis considered a critical crustacean parasitic disease of clinical importance to cultured *C. auratus auratus*. However, the occurrence of the disease in pre-monsoon season (summer) may prove the seasonal impact on the pathogenesis of such disease condition. Periodical screening, quarantine and fish must closely be inspected for the presence of the parasite at the time of purchasing for preventing the disease among cultured Red Can Oranda Gold Fish species irregularly and periodically recommended.

Acknowledgements:

One of author (MS) is thankful to the University Grants Commissions, New Delhi for financial support under SAP.

Conflict of Interests:

The authors declare that there is no conflict of interests regarding the publication of this paper.

References

1. Abd, el-Mohsen., H, Mohamed. and Amany, M. 2013. Studies on argulosis in some freshwater ornamental fishes with special reference to treatment trials. *New York Science Journal*, 6(10) 37-41.
2. Abele, L.G. 1982. *The biology of Crustacea. Systematic, the fossil record, and biogeography.* Academic Press, New York.
3. Al-Dulaimi, F.H.A. 2010. Infection with a Fish Louse *Argulus foliaceus* L. in A Gold Fish (*Carassius auratus*) at Earthen Ponds and Aquarium Fish in Babylon Province, Iraq. *Journal of Babylon University/Pure and Applied Science/ No. (2)/ Vol. (18): 2010.*
4. Ali Adnan, AL-Darwesh1, Maytham, A., Alwan, Al-Shabbani and Bushra, H. F. 2014. Diagnostic and pathological study of *Argulus japonicas* in goldfish (*Carassius auratus*). *G.J.B.B., VOL.3 (4) 2014: 384-387*
5. Azadikhah, D., Masoumian, M., Motallebi, A. A., Male, K M. 2009. Survey of parasitic infection of pikeperch (*Sander lucioperca*) in Aras Reservoir (west Azerbaijan). *Proc 1st Int Congr Aquat Anim Health Manag Dis Teh Iran.*
6. Bauer, R. 1991. *Erkrankungender Aquarien fishe.* Verlag Paul Parey. Berlin and Hamburg.
7. Behrouzfar, I., Sharefian, B., Goodarzi, M. A. 2009. Study on the parasitic Infections of Aquarium Fishes. *Proc 1st Int Congr Aquat Anim Health Manag Dis Teh Iran.*
8. Buchmann K, Bresciani J. 1997. Parasitic infections in pond-reared rainbow trout *Oncorhynchus mykiss* in Denmark. *Int Res Dis Aquat Org.* 28:125-138.
9. Burgu, A., Oguz, T. 1984. The results of parasitological examination of *Carassius* fish. (in Turkish) *Ankara Univ J Vet Fac.* 31:197-206.
10. Burgu, A., Oguz, T., Korting, W., Guralp, N., *Mikrobiyol.* 1988. *Ankara Univ Vet Fak Derg.* 6, 143-166.
11. Bykhovskaya-Pavlovskaya IE, Gusev AV, Dubinina MN, Izyumova NA, Smirnova TS, Sokolovskaya IL, Shtein GA, Shulman SS, Epstein VM. 1964. Key to Parasites of Freshwater Fish of the U.S.S.R. Leningrad.
12. Bykhovskaya-Pavlovskaya, I. E.; Gusev, A. V.; Dubinina, M. N.; Izyumova, N. A.; Smirnova, T. S.; Sokolovskaya, I. L.; Shtein, G. A.; Shulman, S. S. and Epshtein, V. M. 1962. Key to parasites of freshwater fish of the U.S.S.R. *Akad. Nauk, S.S.S.R., Moscow: 727 pp.* (In Russian).
13. Chanda, M., Paul, M., Maity, J., Dash, G., Sen, S., Bidhan, G. and Patra, C. 2011. Ornamentalfish goldfish, *Carassius auratus* and related parasites in three districts of West Bengal, India. *Chron Young Sci* 2011 2(1):51-54.
14. Eissa, I.; Badran, A.; Aly, S.; Abd El-Eal, A.A. and Heba, A.A. 2002. Clinical studies on parasitic diseases among some ornamental fishes and their associated pathological lesions. *Suez Canal Vet. Med. J.* 301-322
15. Eissa, I.A.M. 2002. Parasitic fish diseases in Egypt. *El-Nahda El-Arabia Publisher, 32 Abd El-Khalek Tharwat Street, Cairo, Egypt.*
16. Eissa, I.A.M., and Mohamed, A.H. 2004. Studies on argulosis among some ornamental fishes with special reference to treatment, *SCVMJ, VII (1), 211-216*
17. Ekingen, G. 1976. Some parasites found on European catfish (*Silurus glanis* L.) and brown trout (*Salmo trutta* L.) in Turkey. *Firat Üniv. Vet. Fak. Derg., 3: 112-115.*
18. Geldiay, R., Balik, S. 1974. Mainly endo and ectoparasites observed on the fresh water fish in Turkey (in Turkish). *Ege Univ. Matbaası, Izmir.*

19. Jaameei, M., Khanbabazade H., Notash S. 2009. Case report of infection with *Argulus* in gold fish from fish farms. Proc 1st Int Congr Aquat Anim Health Manag Dis Teh Iran.
20. Kaur, P., Pandey, S. 2014. Effect on marketability of ornamental fishes due to parasitic infection. Biolife 2(4):1094-1099
21. Lucky, Z. 1977. Methods for the diagnosis of fish diseases Amerial Publication Co.PVT, Ltd, New Delhi and New York.
22. Margolis, L., Esch, G.W., Holmes, J.C., Kuris, A.M. and Schad, G.A. 1982. The use of Ecological Terms in Parasitology (Report on an ad-hoc Committee of the American Society of Parasitologists), Journal of Parasitology, 68, 131-133.
23. Mayer, J., Hensel, P., Meji-Fava, J., Brando, J., and Divers, S. 2013. The Use of Lufenuron to Treat Fish Lice (*Argulus sp*) in Koi (*Cyprinus carpio*). J Exot Pet Med, volume 22, issue 1, January 2013, Pages 65-69.
24. Mehdizadeh, M.S. 2009. Study of ectoparasite infestation of 10 common imported freshwater ornamental fish species. PhD Thesis, University of Tehran, Tehran, Iran.
25. Mokhayer, B. 2006. Disease of cultured fish, University of Tehran press, 5th edition, pp. 432 [in Persian].
26. Mokhayer, B., Mousavi, H.E. 2009. Fish lice (*Argulus spp.*) from ichthyofauna of Iran. Proc 1st Int Congr Aquat Anim Health Manag Dis Teh Iran.
27. Molnar, K., Szekely, C. 1998. Occurrence of skrjabillanid nematodes in fishes of Hungary and in the intermediate host, *Argulus foliaceus* L. Acta Vet Hung. 1998; 46:451.
28. Mosafer, S., Khoshnood, Z., 2009. Infection of the Persian sturgeon, *Acipenser persicus* with crustacean parasite: *Argulus sp.* Proc 1st Int Congr Aquat Anim Health Manag Dis Teh Iran.
29. Mousavi, H.E. 2003. Parasites of Ornamental fish in Iran. Bull Eur Ass Fish Pathol 23(6):297-300.
30. Mousavi, H.E., Behtash, F., Bashman, M.R., Mirzargar, S.S., Shayan, P. and Rahmatiholasoo, H. 2011. Study of *Argulus spp.* infestation rate in Goldfish, *Carassius auratus* (Linnaeus, 1758) in Iran. HVM *BIOFLUX*, 2011. Volume 3, Issue 3.198-204.
31. Noaman, V., Chelongar, Y., Shahmoradi, A.H. 2010. The First Record of *Argulus foliaceus* (Crustacea: Branchiura) Infestation on Lionhead Goldfish (*Carassius auratus*) in Iran. Iranian J Parasitol: Vol. 5, No. 2, 2010, pp 71-76.
32. Noga, E. J. 2010. Fish disease Diagnosis and Treatment. 2nd Edition Mosby-yearbook, Inc. watsworth publishing Co., USA. pp.366.
33. Notash, S. 2013. Study on prevalence of *Argulus* in Goldfishes (*Carassius auratus*) of east Azerbaijan province of Iran. Ann Biol Res, 3(7):3444-3447.
34. Peyghan, R., 1999. Fish Parasites and Fish Parasitological disease. Noorbakhsh publications. Tehran, Iran.
35. Purivirojkul, W. 2012. Histological Change of Aquatic Animals by Parasitic Infection. "Histopathology – Reviews and Recent Advances" book edited by Enrique PobletMartinez, ISBN 978-953-51-0866-5, and Published: December 5, 2012 under CC BY 3.0 license. 179-180.
36. Richards, R. 1977. Diseases of aquarium fish- 2. Skin diseases. Vet Rec.; 101:132-135.
37. Rushton-Mellor, S. K. 1994. The genus *Argulus* (Crustacea: Branchiura) in Africa: identification keys. Syst Parasitol 28:51-63.
38. Sarieyyupoglu, M., Saglam, N. 1991. *Ergasilus sieboldi* and *Argulus foliaceus* observed on *Capoeta trutta* caught in the polluted region of Keban Dam Lake (in Turkish). E U J Fish Aquat Sci. 8:143-154.
39. Sharma, M., Shrivastav, A.B., Sahni, Y.P. and Pandey, G. 2012. Overviews of the treatment and control of common fish diseases. Int. Res. J. Pharm .2012,3 (7), p: 123 – 127.
40. Soulsby, E.J.L. 1982. Helminths, Arthropods and Protozoa of Domesticated Animals. 7th ed. Baillière Tindall, London, UK.
41. Toksen, E. 2006. *Argulus foliaceus* (Crustacea: Branchiura) infestation on Oscar, *Astronotus ocellatus* (Cuvier, 1829) and Its Treatment. A case study. E.U. J. Fish. Aquat. Sci., 23:177-179.
42. Vasilean, I., Cristea, V., Dediu, L. 2012. Researches regarding the argulosis treatment to Husk *Huso* juveniles with NaCl. Lucrări Ştiinţifice- Seria Zootehnie, vol. 58: 203-207.
43. Walker, P.D. 2008. *Argulus* the Ecology of a Fish Pest, Ph. D. thesis. Nijmegen: Radboud University; 2008.
44. Yildiz, K., Kumantas, A. 2002. *Argulus foliaceus* infection in a goldfish (*Carassius auratus*). Isr J Vet Med. 57(3):118-120.

DOI: <https://dx.doi.org/10.5281/zenodo.7306506>

Received: 3 October 2015;

Accepted: 18 November 2015;

Available online : 5 December 2015