

## Study of the role of ultrasonography in blunt chest trauma

Mona Abd El baset Mahmoud Khattab<sup>1\*</sup>, Khaled Saad Eldin Karara<sup>2</sup>, Sherif Elsayed Hegab<sup>3</sup>,  
Ayman Ahmed Nosseir<sup>4</sup>

<sup>1</sup>*Emergency Department, Faculty of Medicine University of Alexandria, Egypt*

<sup>2,4</sup>*Cardiothoracic Surgery Department, University of Alexandria, Egypt*

<sup>3</sup>*Radiology Department, University of Alexandria, Egypt*

\*E-mail: [monmon.khattab@yahoo.com](mailto:monmon.khattab@yahoo.com)

### ABSTRACT

The purpose of this investigation was to evaluate the role of thoracic ultrasound for detection of hemopneumothorax and pericardial collection and treatment in patients with blunt chest trauma. This study included 50 patients admitted to Emergency department in alexandria university hospital presented with isolated blunt chest trauma or polytrauma with chest involvement, their age ranged from 16-80 years, 88% of them were males and 12% were females, males are more than females because they are more active & physically more mobile. In our study chest computed tomography was used as a gold standard for diagnosing hemothorax, pneumothorax, pericardial effusion & lung contusion to assess the diagnostic value of chest radiography and lung ultrasonography. This study shows Sensitivity, specificity and accuracy of US & x ray in detecting hemothorax, for US chest Sensitivity was 95.24%, Specificity was 100.0%, PPV was 100.0%, NPV 96.67% & Accuracy was 98.0% compared to chest x -ray Sensitivity was 71.43, Specificity was 100.0%, PPV was 100.0%, NPV 82.86% & Accuracy was 88.0%, For pneumothorax; US chest Sensitivity was 82.76%, Specificity was 100.0%, PPV was 100.0%, NPV 81.48% & Accuracy was 90.2% compared to chest x -ray Sensitivity was 71.43, Specificity was 100.0%, PPV was 100.0%, NPV 73.33% & Accuracy was 84.0%. For lung contusion; US chest Sensitivity was 82.61%, Specificity was 100.0%, PPV was 100.0%, NPV 87.50% & Accuracy was 92.16% compared to chest x -ray Sensitivity was 50.0, Specificity was 100.0%, PPV was 100.0%, NPV 71.79% & Accuracy was 78.0. For pericardial effusion; US chest Sensitivity was 100.0%, Specificity was 100.0%, PPV was 100.0%, NPV 100.0% & Accuracy was 100.0% compared to chest x -ray Sensitivity was 0%, Specificity was 100.0%, PPV was 0%, NPV 94.0% & Accuracy was 94.0%.

**Key words:** Thoracic injuries, blunt cardiac injuries, thoracic trauma

### Introduction

Trauma continues to be an enormous public health problem worldwide and it is associated with high morbidity and mortality both in developed and developing countries.(1) Trauma is reported to be the leading cause of death, hospitalization, and long-term disabilities in the

first four decades of life. Globally, 10% of all trauma admissions result from chest injuries and 25% of trauma-related deaths are attributable to chest injuries.(2)

#### How to Site This Article:

Mona Abd El baset Mahmoud Khattab, Khaled Saad Eldein Hamed Karara, Sherif Elsayed Hegab, Ayman Ahmed Nosseir (2015). Study of the role of ultrasonography in blunt chest trauma in emergency *Biolife*, 3(3), pp 697-701.

Emergency physicians play a vital role in the stabilization and diagnostic phases of trauma care. Often the emergency physician is the sole physician in attendance during the initial phase of resuscitation; what happens in this period often determines the outcome of care.(3)

Blunt chest injuries are common encounters in the emergency department. The injuries can range from the fairly benign to the acutely life threatening, often with no obvious physical signs or symptoms of the underlying pathology. It is helpful to understand the mechanism of injury, to calculate the potential life threats associated with such mechanisms, and to employ the correct diagnostic approach and prudent management of blunt chest trauma and its associated injuries.(4)

The use of ultrasound for the management of the injured patient has expanded dramatically in the last decade. The focused assessment with sonography for trauma (FAST) has become one of the fundamental skills incorporated into the initial evaluation of the trauma patient.

Standard FAST protocols evaluate four regions (pericardial, perihepatic, perisplenic, and pelvis) however it is technically feasible and comparatively simple to expand the scanned areas to formally assess the chest for haemothorax, pneumothorax or pericardial effusion. Sonography has been shown to be useful for diagnosing pleural effusion, pericardial effusions, and pneumothorax.(5-8)

## Material and Methods

### Patients

This prospective study will be conducted on 50 stable patients with blunt chest trauma (any trauma to the chest whether isolated or part of poly trauma) admitted to Alexandria Main University Hospital.

### Method

Prospective study on a group of patients with blunt chest trauma after taking consent of the patients or parents in case of child and all the following steps will be needed:

### *Complete history taking of relatives on admission.*

#### A. Personal data:

- Age
- Gender.
- Date of admission.
- Hospital number.

#### B. Characters of injury:

- Type of trauma.
- Site of trauma.

### *Clinical examination:*

#### A) Primary survey:

- Airway and Cervical spine stabilization.
- Breathing.
- Circulation and Control of hemorrhage.
- Disability (a brief neurological examination).
- Exposure.

#### B) Secondary survey:

The secondary survey is a head-to-toe evaluation of the trauma patient, that is, a complete history and physical examination, including reassessment of all vital signs.

### *Radiological work up.*

1. Chest x-ray P-A.
2. Thoracic & abdominal ultrasonography.
3. Computed tomography.
4. US guided aspiration when needed.

## Results and Discussion

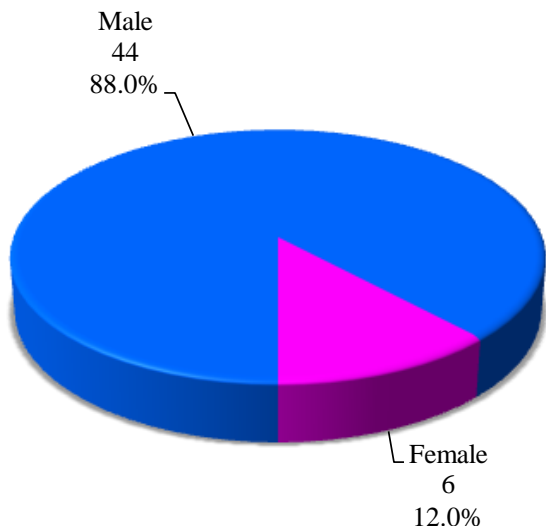
This study included 50 patients admitted to Emergency department in Alexandria Main University Hospital with isolated blunt chest trauma or polytrauma with chest involvement .

Table-1 shows Sensitivity, specificity and accuracy for hemothorax in US and X-ray Shows for US chest Sensitivity was 95.24% , Specificity was 100.0% , PPV was 100.0% , NPV 96.67% & Accuracy was 98.0% compared to chest x -ray Sensitivity was 71.43, Specificity was 100.0% , PPV was 100.0% , NPV 82.86% & Accuracy was 88.0% .

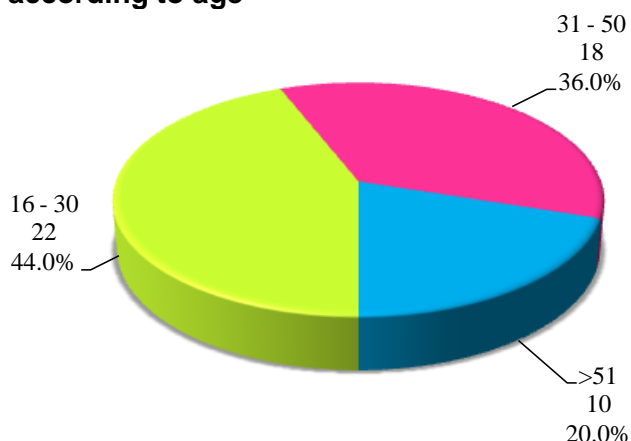
The sensitivity, specificity and accuracy for hemothorax in US and X-ray Shows for US chest Sensitivity was 95.24% , Specificity was 100.0% , PPV was 100.0% , NPV 96.67% & Accuracy was 98.0% compared to chest x -ray Sensitivity was 71.43, Specificity was 100.0% ,

PPV was 100.0% , NPV 82.86% & Accuracy was 88.0% (table1).

**Figure-1. Distribution of the studied cases according to sex**



**Figure-2. Distribution of the studied cases according to age**



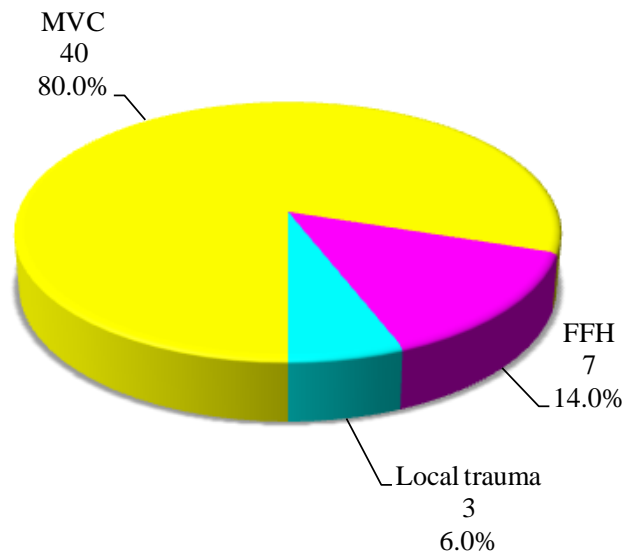
**Table-1. Sensitivity, specificity and accuracy for hemothorax in US and X-ray.**

	Hemothorax US	Hemothorax X-ray
Sensitivity	95.24	71.43
Specificity	100.0	100.0
PPV	100.0	100.0
NPV	96.67	82.86
Accuracy	98.0	88.0

. Comparing this study to another study, Rothlin, et al reported an 81% sensitivity, 100%

specificity, and 99% accuracy for detection of hemothorax by ultrasonography.(9)

**Figure-3. Distribution of the studied cases according to mode of trauma**



The sensitivity, specificity and accuracy of US & x ray in detecting pneumothorax , for US chest Sensitivity was 82.76% , Specificity was 100.0% , PPV was 100.0% , NPV 81.48% & Accuracy was 90.2% compared to chest x -ray Sensitivity was 71.43, Specificity was 100.0% , PPV was 100.0% , NPV 73.33% & Accuracy was 84.0%(table2). %. Our results from a large series of trauma patients confirm previous studies and demonstrate that bedside US performed by the clinician in charge provides a higher sensitivity and accuracy in detection of pneumothorax than portable supine CXR. Dulchavsky et al, at Detroit Receiving hospital, published a case report followed by prospective study of case using US for this purpose.(10)

**Table-2. Sensitivity, specificity and accuracy of US & x ray in detecting pneumothorax , for US chest Sensitivity**

	Pneumothorax US	Pneumothorax X-ray
Sensitivity	82.76	71.43
Specificity	100.0	100.0
PPV	100.0	100.0
NPV	81.48	73.33
Accuracy	90.2	84.0

The sensitivity, specificity and accuracy of US & x ray in detecting pericardial effusion , for US chest Sensitivity was 100.0%, Specificity was 100.0%, PPV was 100.0%, NPV 100.0% & Accuracy was 100.0% compared to chest x -ray Sensitivity was 0%, Specificity was 100.0% , PPV was 0% , NPV 94.0% & Accuracy was 94.0%(table3). This result is in accordance with Symbas et al show sensitivity of FAST for cardiac injury (n = 8) in patients with pericardial effusion was 100% & specificity was 100%. The presence of pericardial effusion determined by FAST correlated with the need for thoracotomy in 7 (87.5%) of 8 patients.(11)

**Table-3. Sensitivity, specificity and accuracy of US & X ray in detecting pericardial effusion, for US chest Sensitivity**

	Pericardial effusion US	Pericardial effusion X-ray
Sensitivity	100.0	0
Specificity	100.0	100.0
PPV	100.0	-
NPV	100.0	94.0
Accuracy	100.0	94.0

The sensitivity, specificity and accuracy of US & x ray in detecting lung contusion, for US chest Sensitivity was 82.61%, Specificity was 100.0%, PPV was 100.0%, NPV 87.50% & Accuracy was 92.16% compared to chest x -ray Sensitivity was 50.0, Specificity was 100.0% , PPV was 100.0%, NPV 71.79% & Accuracy was 78.0%(table4). In another study by Lichtenstein (12) which was about The Comet-tail Artifact An Ultrasound Sign of Alveolar-Interstitial Syndrome, Ultrasonography had a sensitivity of 92.5% and a specificity of 65.1% for diagnosing radiologic alveolar-interstitial syndrome.

**Table-4. Sensitivity, specificity and accuracy of US & x ray in detecting lung contusion, for US chest Sensitivity**

	Lung contusion US	Lung contusion X-ray
Sensitivity	82.61	50.0
Specificity	100.0	100.0
PPV	100.0	100.0
NPV	87.50	71.79
Accuracy	92.16	78.0

Thoracic ultrasound has several advantages over traditional radiographic imaging of the pleura, including absence of radiation, better portability, real-time imaging, and the ability to perform dynamic imaging.

Compared with CT scanning, ultrasound may better differentiate pleural fluid from pleural thickening and pleural masses.(13) Bedside thoracic ultrasound is also faster and less resource-demanding than transporting a critically-ill patient to the CT scanner.(14)

Ultrasound examination of the pleura is more sensitive than a plain chest radiograph at detecting the presence of pleural fluid and differentiating pleural fluid from lung consolidation. Compared with computed tomography (CT), pleural ultrasound has a 95 percent sensitivity for detection of pleural disease in patients with a “white out” on plain chest radiograph, but is slightly less sensitive in detecting small amounts of fluid.(15,16)

## Conclusion

Thoracic ultrasound has several advantages over traditional radiographic imaging of the pleura, including absence of radiation, better portability, real-time imaging, and the ability to perform dynamic imaging. Compared with CT scanning, ultrasound may better differentiate pleural fluid from pleural thickening and pleural masses. Bedside thoracic ultrasound is also faster and less resource-demanding than transporting a critically-ill patient to the CT scanner.

## Conflict of Interests:

The authors declare that there is no conflict of interests regarding the publication of this paper.

## References

1. Park K: Accidents. In Textbook of Social and Preventive Medicine. 17 edition. Edited by: Park K. Jabalpur: Banarsidas Co; 2000:304-5.
2. Miller DL, Mansour KA: Blunt traumatic chest injuries. Thoracic Surgery Clinics 2007; 17:57-61.

3. Kivioja AH, Myllynnenn PJ, Rokkanen PU: Is the treatment of the most severe multiply injured patients worth the effort? *J Trauma* 1990; 30: 480.
4. Clancy TV, Maxwell JG, Covington DL. A statewide analysis of level I and level II trauma centers for the patients with major injuries. *J Trauma*. 2001; 51: 346-51.
5. Ma OJ, Mateer JR. Trauma ultrasound examination versus chest radiography in the detection of haemothorax. *Ann Emerg Med* 1997; 29:312–6.
6. Blaivas M, DeBehnke D, Phelan MB. Potential errors in the diagnosis of pericardial effusion on trauma ultrasound for penetrating injuries. *Acad Emerg Med* 2000; 7:1261–6.
7. Nandipati KC, Allamaneni S, Kakarla R, et al. Extended focused assessment with sonography for trauma (EFAST) in the diagnosis of pneumothorax: experience at a community based level I trauma center. *Injury* 2010;41:862–865.
8. American College of Emergency Physicians. Emergency ultrasound guidelines – 2008. *Ann Emerg Med*. 2009; 53:550-570.
9. Rothlin MA, Naf R, Amgwerd M, Candinas D, Frick T, Trentz O. Ultrasound in blunt abdominal and thoracic trauma. *J Trauma* 1993; 34: 488-95.
10. Dulchavsky SA, Schwarz KL, Kirkpatrick AW, Billica RD, Williams DR, Diebel LN, et al. Prospective evaluation of thoracic ultrasound in the detection of pneumothorax. *J Trauma* 2001; 50: 201-5.
11. Symbas NP, Bongiorno PF, Symbas PN. Blunt cardiac rupture: the utility of emergency department ultrasound. *Ann Thorac Surg* 1999; 67: 1274-6.
12. Lichtenstein D, Lascols N, Mezière G, Gepner A. Ultrasound diagnosis of alveolar consolidation in the critically ill. *Intens Care Med* 2004; 30: 276-81.
13. Ugalde, P., Camargo, J. D. J., & Deslauriers, J. (2007 November) Lobes, Fissures, and Bronchopulmonary Segments. 17 (4), 587-599.
14. Feller-Kopman D. Ultrasound-guided thoracentesis. *Chest*. 2006;129:1709-14.
15. Ferreira AC. The role of ultrasound in the assessment of pleural effusion. *Radiol Bras*. 2006;39:145-50.
16. Yu CJ, Yang PC, Wu HD. Ultrasound study in unilateral hemithorax opacification. Image comparison with computed tomography. *Am Rev Respir Dis*. 1993;147:430-34.

DOI: <https://dx.doi.org/10.5281/zenodo.7294486>

Received: 8 July 2015;

Accepted: 24 August 2015;

Available online : 7 September 2015